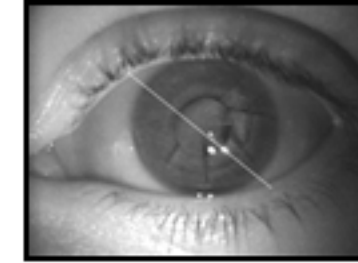


Image Analysis Report



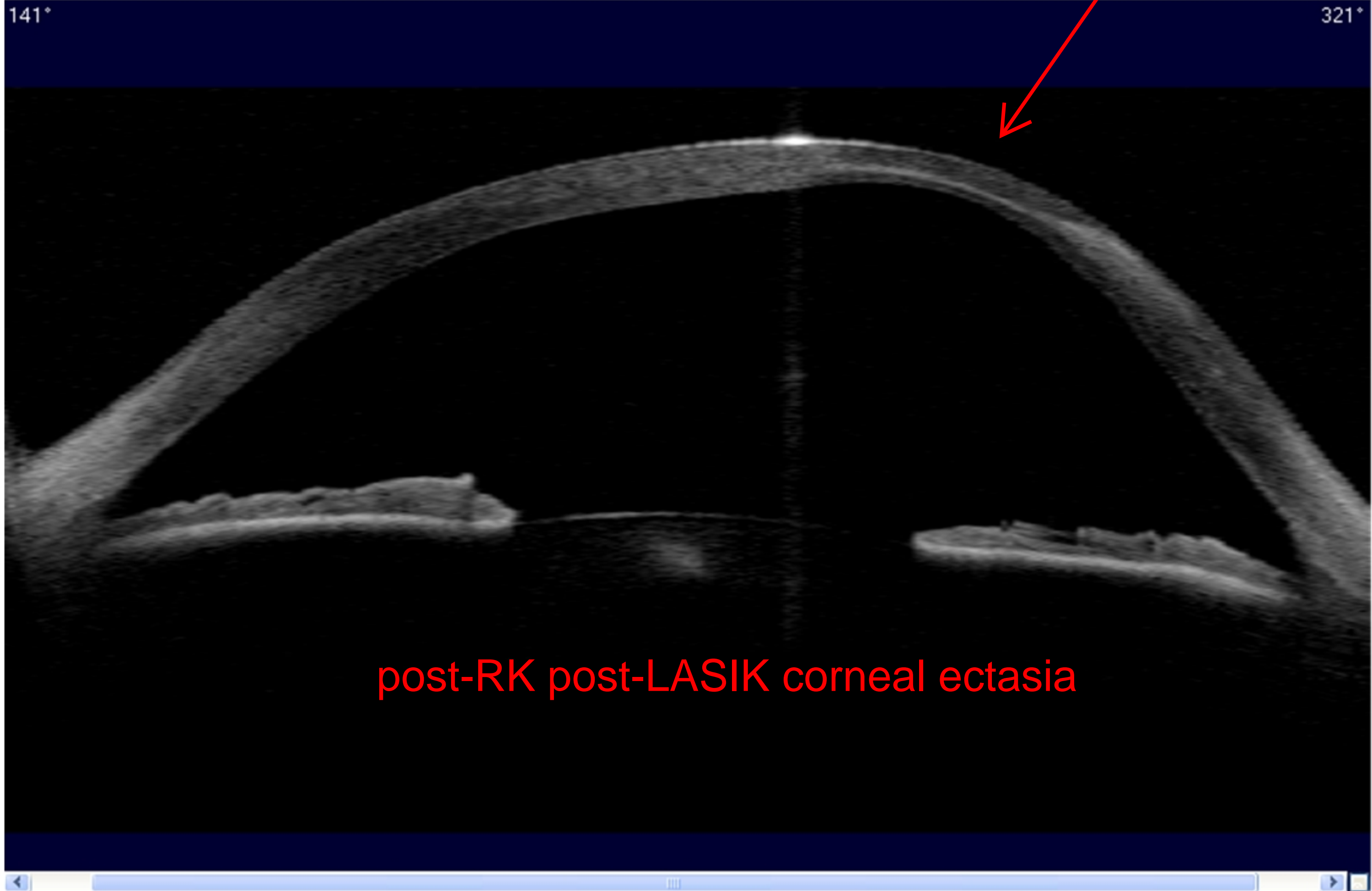Patient name: [REDACTED]
Date of birth: [REDACTED]
Patient ID: [REDACTED]

Rx: Sphere: 0.0
Cylinder: 0.0
Axis: 0.0
Fixation Angle: 0.0
Polarization: 31.0
Orientation: 321.0
Protocol: Edward Boshnick, O.D.
Scan: Enhanced Anterior Segment Single



Visante™ OCT
ANTERIOR SEGMENT IMAGING

Exam date: 2/12/2010 1:28:21 PM



Planning

Institution: CZM Date: 2/12/2010 1:30:37 PM Serial Number: 1000-1815
Planner: VisanteTech Station: Software Ver: 3.0.0.139

Acquisition

Institution: CZM Serial Number: 1000-1815
Operator: VisanteTech Station: Software Ver: 3.0.0.139