

# Image Analysis Report



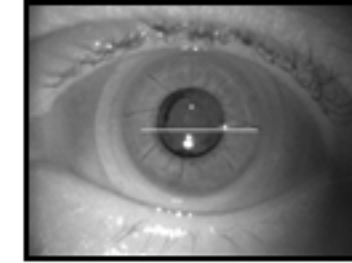
Patient name:



Date of birth:

Patient ID:

Rx: Sphere: 0.0  
Cylinder: 0.0  
Axis: 0.0  
Fixation Angle: 0.0  
Polarization: 35.0  
Orientation: 0.0




OS

Visante™ OCT  
ANTERIOR SEGMENT IMAGING

Exam date: 7/16/2010 11:47:04 AM

Protocol: Edward Boshnick, O.D.  
Scan: Enhanced High Res. Corneal



## Planning

Institution:

Date: 7/16/2010 11:50:57 AM

Serial Number: -

Planner:

Station:

Software Ver:

## Acquisition

Institution: CZM

Serial Number: 1000-1815

Operator: VisanteTech

Station:

Software Ver: 3.0.0.139