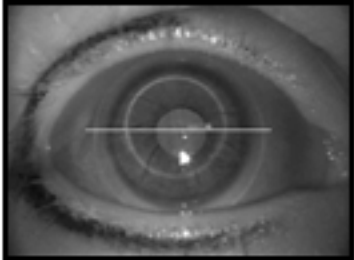


Image Analysis Report



Patient name: [REDACTED]
Date of birth: [REDACTED]
Patient ID: 11173

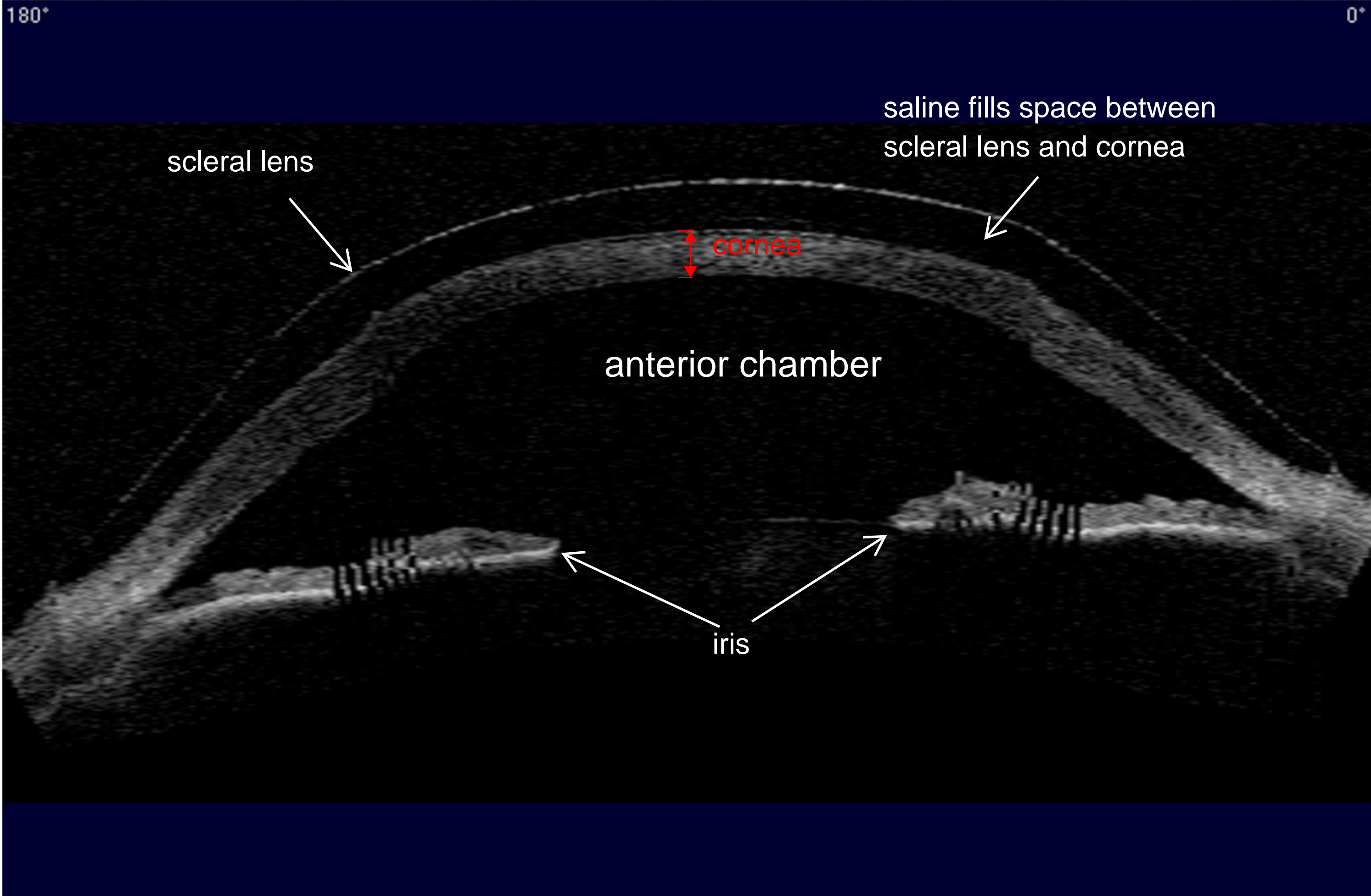
Rx: Sphere: 0.0
Cylinder: 0.0
Axis: 0.0
Fixation Angle: 0.0
Polarization: 41.0
Orientation: 0.0



OD

Visante™ OCT
ANTERIOR SEGMENT IMAGING

Exam date: 12/15/2009 2:13:06 PM Protocol: Edward Boshnick, O.D.
Scan: Anterior Segment Single



Planning

Institution: Date: 1/4/2010 9:52:00 AM Serial Number: -
Planner: Station: Software Ver:

Acquisition

Institution: CZM Serial Number: 1000-1815
Operator: VisanteTech Station: Software Ver: 3.0.0.139